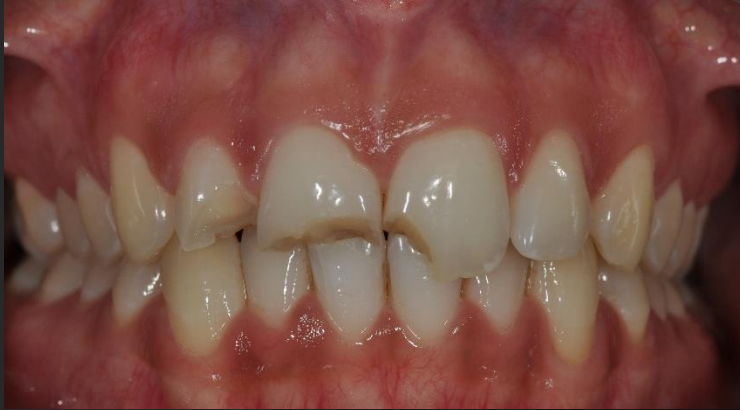
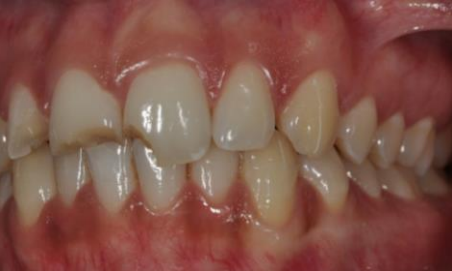
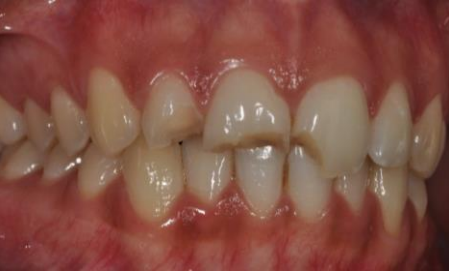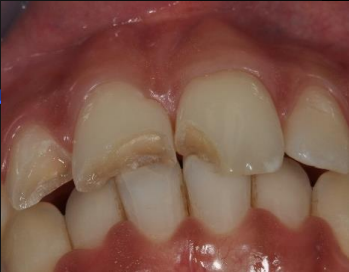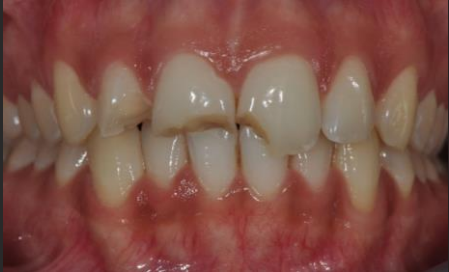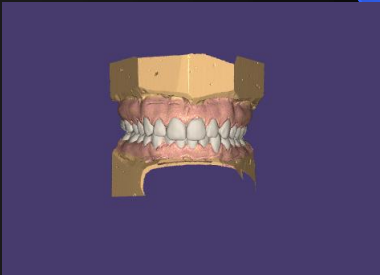
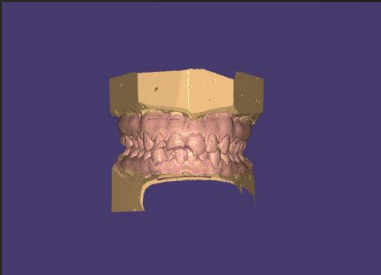
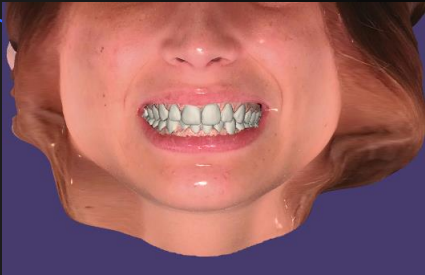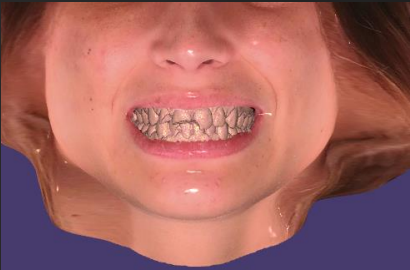Pre-op: aesthetic area trauma



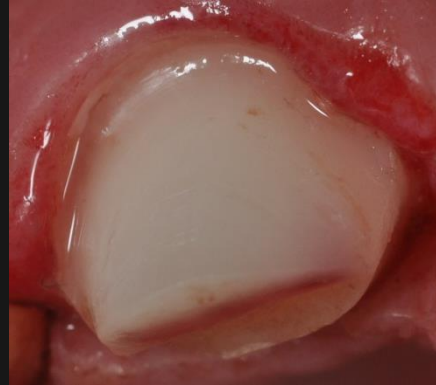
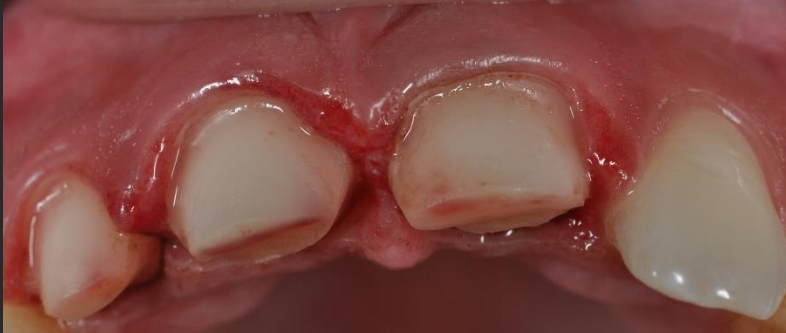Pre-op: aesthetic area trauma



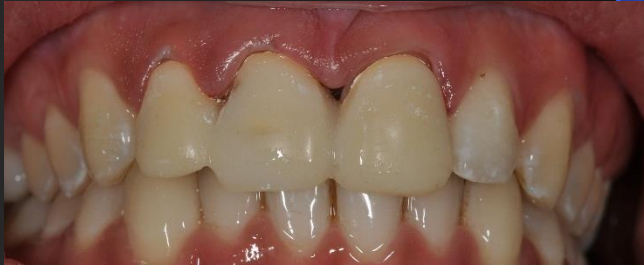Pre-op: Facial scanner; smile design planning



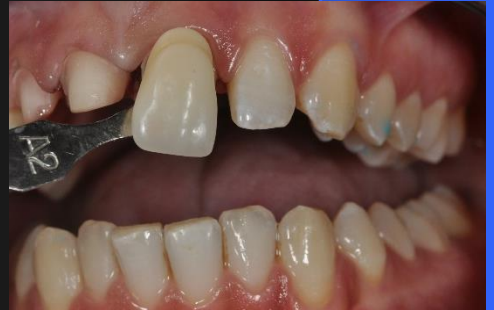
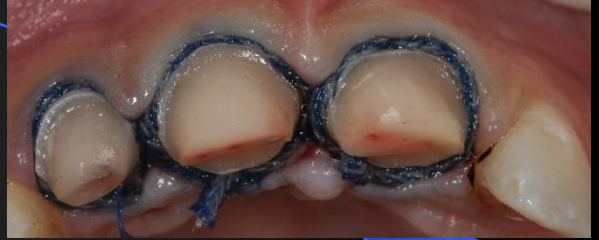Prosthetic preparation of the abutments



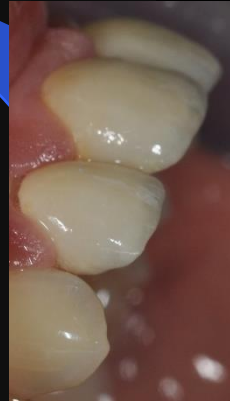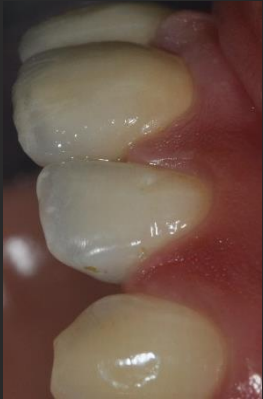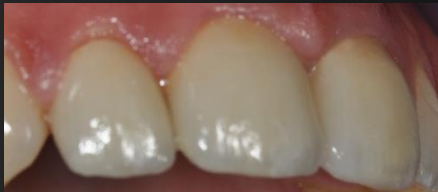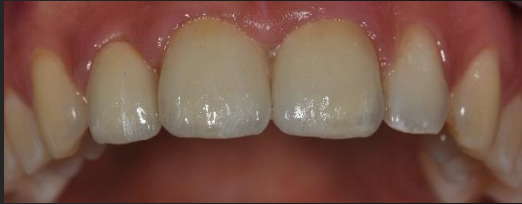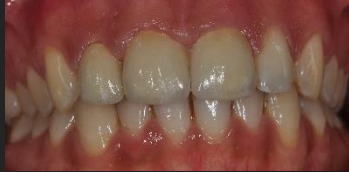Resin Temporary rehabilitation



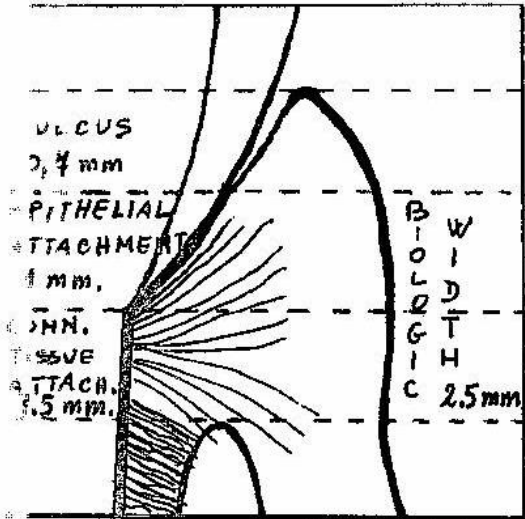
Prosthetics phases



Aesthetics considerations and remarks

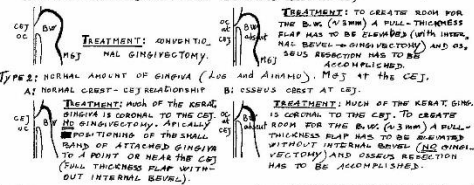


Prosthetic Planning



CLASSIFICATION OF ALTERED PASSIVE ERUPTION IN THE ADULT.

- **TYPE 1:** EXCESSIVE AMOUNT OF GINGIVA. WIDER GINGIVA DIMENSION FROM THE FREE MARGIN TO THE MGJ. MGJ IS APICAL TO THE ALVEOLAR CREST.
 - A: NORMAL CREST- CEJ RELATIONSHIP
 - B: OSSIOUS CREST AT CEJ
- **TYPE 2:** NORMAL AMOUNT OF GINGIVA (LOS and AIRMANO). MGJ AT THE CEJ.
 - A: NORMAL CREST- CEJ RELATIONSHIP
 - B: OSSIOUS CREST AT CEJ.

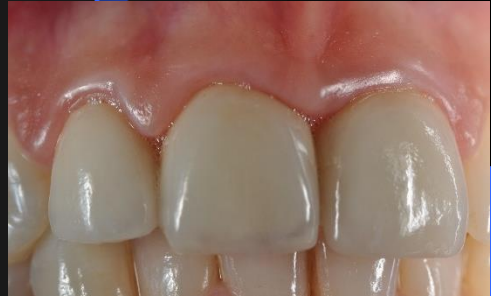
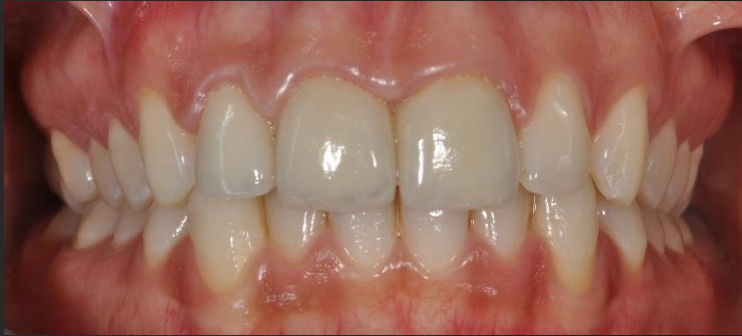
Esthetic CROWN LENGTHENING

- I: GINGIVAL REDUCTION ONLY - BONE REMOVAL NOT REQUIRED.
 - A: GINGIVECTOMY
 - B: GINGIVAL FLAP SURGERY
- II: MUCOPERIOSTEAL FLAP WITH OSTECTOMY - BONE REMOVAL REQUIRED.
 - A: ONE-STAGE PROCEDURES, WHICH REQUIRE ONE OF THE FOLLOWING:
 - 1) FLAPS, OSTECTOMY, APICAL POSITIONING - USEFUL IF THE AMOUNT OF KERATINIZED GINGIVA IS LIMITED.
 - 2) FLAPS, OSTECTOMY, GINGIVECTOMY, POSITIONING.
 - 3) GINGIVECTOMY, FLAPS, OSTECTOMY, POSITIONING -> INTERNAL BEVEL GINGIVECTOMY, AN ADEQUATE AMOUNT OF KERAT. TISSUE MUST REMAIN, PAPILLA PRESERVATION; FULL THICKNESS FLAP; OSTECTOMY WITH 2MM OF BONE REMOVAL; THE FLAP IS THEN POSITIONED AND SUTURED "TO THE NON-VIOLATED PAPPILLAS"
 - B: TWO-STAGE PROCEDURES, WHICH REQUIRE:
 - 1) FLAPS, OSTECTOMY AND REPOSITIONING: REFLECTION OF A FULL-THICKNESS FLAP, MUCULOCUTANEOUS INCISION, PAPPILLAS ARE PRESERVED, VERTICAL INCISION; BONE REMOVAL; REPOSITIONING OF THE FLAP.
 - 2) 4 TO 6 WEEKS LATER -> GINGIVECTOMY -> THE ALVEOLAR CREST IS SOUNDED AND THE MILLIMETERS OF SUPRA-ALVEOLAR GINGIVAE DETERMINES. THIS NUMBER MINUS 3MM. IS THE AMOUNT OF GINGIVA THAT CAN BE REMOVED WITH NO CHANGE IN THE FREE GINGIVAL MARGIN.

REFERENCES: The Diagnosis and Treatment of the Gumy Smile (Robert A. Lowe, Michael Mc Guire - Compendium - Vol. XVII, N°8 - Aug. 87. - pag. 757-764)
 Esthetic Crown Lengthening for maxillary anterior teeth (Michael Souier - Compendium - Vol. XVII, N°8 - Aug. 87. - pag. 802-813).

Follow-up, two months post op



Follow-up, four months post-op. After teeth whitening

